



TINA JAKOB

PRELIMINARY BIOARCHAEOLOGICAL ANALYSIS OF THE HUMAN REMAINS FROM MOGRAT ISLAND (MOG034), 2014 AND 2015

INTRODUCTION

This preliminary report summarises the bioarchaeological analysis of human skeletal remains excavated by the Mograt Island Archaeological Mission (MIAMi) at site MOG034 in 2014 and 2015.¹ MOG034 has yielded a number of cemeteries belonging to different time periods² and to date (September 2015), 43 of the excavated 52 skeletons have been analysed in Khartoum, where the human remains are curated.

MATERIALS AND METHODS

Not all graves could be dated to a specific archaeological period, but where possible results for individuals belonging broadly to the same period were summarised to avoid overgeneralisations, since the different cemeteries are spanning approximately 3000 years. Radiocarbon dates for a small cemetery, feature F072, testify the earliest burials, dated to the Terminal Neolithic,³ while F004–F008 and F025 SK01 belong to the Kerma period.⁴ The remaining features can currently not be dated more precisely than being of late New Kingdom – Napatan/Early Meroitic date, except F025 SK03 which was radiocarbon-dated to the early Meroitic period.⁵ The human remains were analysed using a standard protocol based on published guidelines.⁶ In particular, skeletal preservation and completeness, age and sex estimation, stature estimation and a palaeopatholog-

ical assessment of dental and skeletal conditions are presented here.

THE TERMINAL NEOLITHIC CEMETERY F072

This small cemetery consisted of 22 individuals, many of them fragmentary and incomplete, due to grave robbing.⁷ However, overall the skeletal preservation was good which allowed a detailed bioarchaeological analysis. Fourteen (63.6%) individuals did not reach adulthood, which is a high percentage, although this might be an artifact of the small sample size. In contrast, at the much larger Late Neolithic cemetery R12 in the Northern Dongola Reach, 28% of individuals were under the age of 18 years.⁸ Of the eight adults, four were male, three female and one individual was of undetermined biological sex. Non-adults ranged in age from only a few months old to early teens or older, while none of the adults reached middle age (35+ years), with four dying as young adults (17–25 years) and four as young-middle adults (26–35 years). Again this can be contrasted with cemetery R12, where 22% of adults died between 35–50 years.⁹

Stature estimation was possible for seven individuals (three females and four males). Due to the high fragmentation of long bones used in traditional stature calculation (femur and tibia), regression formulae utilising metacarpals and metatarsals were employed.¹⁰ Average stature for male individuals was 164.43cm (range 162.31–167.76cm), while women reached on average of 159.6cm (range 159.26–160.04cm). However, the small sample size and high standard deviation of measurements need to be taken into account.

1 I am grateful to all field team members, especially Gareth Rees and Jens Weschenfelder, for sharing photographs and contextual information. Particular thanks go to Claudia Näser for the opportunity to study the human remains from MOG034.

2 Weschenfelder and Rees 2014; Weschenfelder, this volume.

3 Weschenfelder and Rees 2014: 153.

4 Weschenfelder and Rees 2014: 150.

5 Weschenfelder, this volume.

6 Buikstra and Ubelaker 1994, sex estimation: figs. 1–4; age estimation: figs. 13, 20, 24–26.

7 Weschenfelder and Rees 2014: 151.

8 Judd 2008: 96.

9 Judd 2008: table 8.18.

10 Byers 2010: 262 (metacarpals), 263 (metatarsals).




Fig. 1: Linear enamel hypoplasia on left maxillary central incisor (tooth on left side) of F072 SK08 (photo: Tina Jakob)



Fig. 2: Cribra orbitalia on right orbital roof of F072 SK08 (photo: Tina Jakob)

Dental health of the six adults with at least one observable tooth was good with no caries lesions present. However, male individual F072 SK03 had a large periapical lesion. Three of the six adults (50.0%) had mineralised dental plaque (calculus) with seven teeth affected out of a total of 124 (5.6%). Periodontal disease was observed in only one individual, F072 SK15, a young-middle adult male.

Linear enamel hypoplasia (fig. 1) indicating non-specific stress during tooth formation in childhood¹¹ was present in seven of the 15 individuals with observable permanent teeth (46.7%) or 53 of 197 permanent teeth (26.9%). Cribra orbitalia (fig. 2), also commonly used to indicate substandard health and nutrition in childhood¹² was only seen in non-adults (four of six individuals with preserved orbital roofs, or 66.7%, were affected), while none of the three

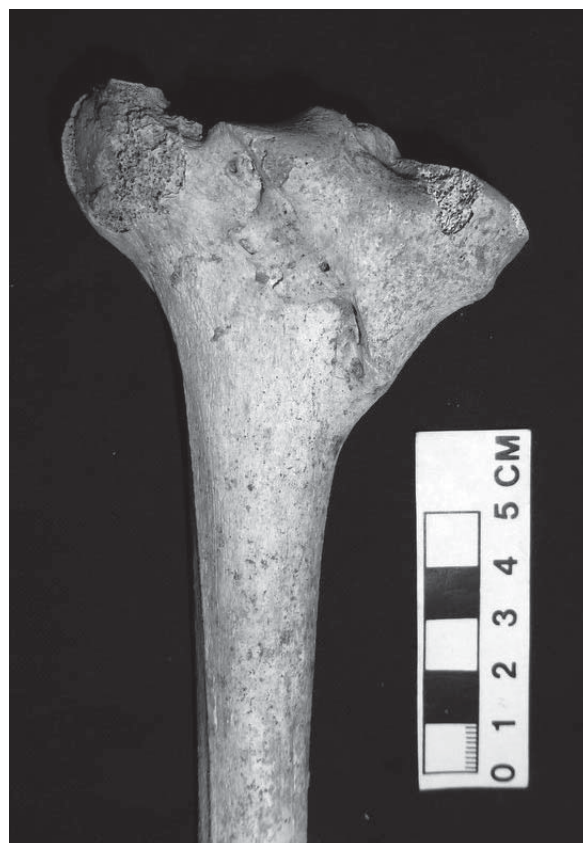

Fig. 3: Healed compression fracture of left tibia of F072 SK10A (photo: Tina Jakob)

adults with this skeletal element showed any signs of the condition.

Neural arch defects of the sacral segments occurred in two of the three adults with observable sacra; all of them were females. While the resulting defect would have been bridged by soft tissue during life, the presence of neural arch defects can indicate mineral deficiency (e.g. folate acid, zinc and selenium) during intrauterine development in combination with a congenital predisposition, biological isolation or endogamy.¹³ Symphalangism, or congenital fusion of the intermediate and distal foot phalanges,¹⁴ was found in two individuals (one adult and one non-adult) of 13 individuals with foot bones present.

Only one individual, F072 SK10A, a young adult female, showed evidence for healed trauma. She had sustained a compression fracture of the medial condyle of the left tibia and although the injury had eventually healed, there were signs of infection in form of pitting and new bone formation (fig. 3). This rare type of injury today is most often seen in high velocity accidents or falls from heights.¹⁵

11 Larsen 2015: 33.

12 Roberts and Manchester 1995: 166–169.

13 Simalcsik et al. 2011: 133–134.

14 Judd 2001: 494.

15 Solomon 2015: 891.



With the exception of post-traumatic infection seen in SK10A, none of the individuals buried in the Terminal Neolithic cemetery of F072 showed any signs for infectious disease or joint disease. However, evidence for non-specific stress (linear enamel hypoplasia and cribra orbitalia) indicates high levels of childhood malnutrition and disease. The high percentage of non-adults buried at F072 could indicate specific funerary practices where certain areas were reserved for the burial of non-adults, but high childhood mortality and fertility rates have to be considered as well.¹⁶

KERMA PERIOD BURIALS

Six¹⁷ individuals were dated to the Kerma period based on grave structures and few grave goods.¹⁸ All of them were adults, with five males and one female. Three individuals (two males and the female) were aged over 35 years, with the remaining individuals belonging to the 26–35 year age category. Unlike at F072, no non-adults were present and a much wider range of pathological conditions was observed, despite similar levels of preservation and skeletal completeness. Stature estimation was possible for all individuals; males were 164.7cm (range 159.55–170.51cm) and the female was 167.75cm tall. However, the small sample size does not allow for any conclusive observations and the fact that the only female was taller than the male average must be taken with caution. In comparison, Judd noted an average stature of 170.18cm for males and 163.58cm for females in the Northern Dongola Reach.¹⁹

Only three individuals had teeth preserved, although four individuals had at least one alveolar socket available for observation. Again, dental caries was absent, but two individuals had calculus affecting seven of the observable 22 teeth. Two individuals had ante-mortem tooth loss, affecting two out of 53 tooth positions (3.8%). Only one individual (F008 SK01) suffered from periodontal disease. Two individuals had periapical lesions (fig. 4), affecting seven of 53 tooth positions, or 13.2%. F008 SK01, an old adult female, had six lesions, while F025 SK01 had one lytic lesion surrounding the tips of the tooth roots. In the absence of dental caries and exposure of the dental

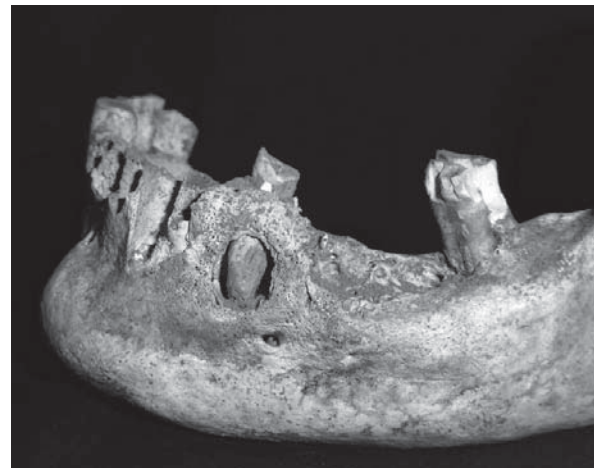

Fig. 4: Periapical lesion on left mandible of F008 SK01 (photo: Tina Jakob)



Fig. 5: New bone formation on inner aspect of left rib of F025 SK01 (photo: Tina Jakob)

pulp through advanced dental wear, the possibility that microscopic cracks allowed bacteria to infiltrate the tooth and spread to the underlying alveolar bone has to be considered.²⁰

One individual (F005 SK01) had linear enamel hypoplasia, with five teeth being affected and the same individual also had cribra orbitalia (out of five individuals with orbital roofs preserved). New bone formation, also classified as a non-specific stress indicator was seen in three individuals, affecting the ectocranial occipital and parietal bones, both proximal fibulae and the right tibia, respectively. All lesions were healed, indicating that whatever caused this bony response was no longer active at the time of death of these individuals.

Respiratory health was affected in three individuals (F005 SK01, F008 SK01 and F025 SK01). Two individuals of six with observable ribs had extensive new bone formation on the visceral (inner) side of their ribs (fig. 5), indicating a healed infection of the lungs, while the old adult female had chronic

16 Lewis and Gowland 2007: 118.

17 Only six individuals have been analysed so far (F004 SK01, F005 SK01, F006 SK01, F007 SK01, F008 SK01, F025 SK01), although F028 SK01 is also dated to the Kerma period – see Weschenfelder, this volume.

18 Weschenfelder, this volume.

19 Judd 2001: table 11.11.

20 I would like to thank dentist Dr. Martin Scheurer for this suggestion and discussion of the topic.



Fig. 6: Spondylolysis affecting fifth lumbar vertebra of F006 SK01 (photo: Tina Jakob)

maxillary sinusitis, although this infection could also have been caused by the spread of bacteria from the periapical lesions she was suffering from.²¹

Congenital conditions were not only restricted to neural arch defects of the sacrum (affecting two of three individuals with sacra). F007 SK01 had six sacral vertebrae instead of five, with the lower two having failed to fuse posteriorly. This individual also had two thoracic vertebrae (T11 and T12) displaying a caudal shift, with both vertebrae having morphological features of a typical lumbar vertebra.²² Sym-

phalangism occurred in one individual of five with foot phalanges present. Two individuals had spondylolysis of the fifth lumbar vertebra (fig. 6), separation of the vertebral neural arch due to trauma caused by bending and lifting forces, but it is thought that an underlying congenital defect causes the weakening and subsequent separation of the neural arch;²³ one was bilateral, while the other occurred unilaterally (seen in two of four observable individuals). Os acromiale (separation of the tip of the acromion process of the scapula caused by trauma) might have the same underlying congenital etiology; this condition was seen in one individual (F025 SK01). An association of os acromiale with the use of bows has been made and while archery was well known during the Kerma period, so far no clinical evidence exists that provides proof.²⁴

The only female individual (F008 SK01) also had the only fracture in this group. The right radius was fractured at the lower end of the shaft and while the fracture had healed well, there was a considerable amount of angulation that could have affected the use of her right arm (fig. 7). Fracture of the radius can occur due to falls on the outstretched hand. However, if a fall was caused by an accident or if the individual was pushed or lost balance during an altercation has to remain unresolved.²⁵

While joint disease did not occur in the Terminal Neolithic group of F072, four of the six Kerma period individuals had degeneration of spinal and/or extra-spinal joints. Since joint degeneration is associated with increasing age, this is not surprising with half of the individuals being classified as older adults. One individual (F007 SK01) had complete

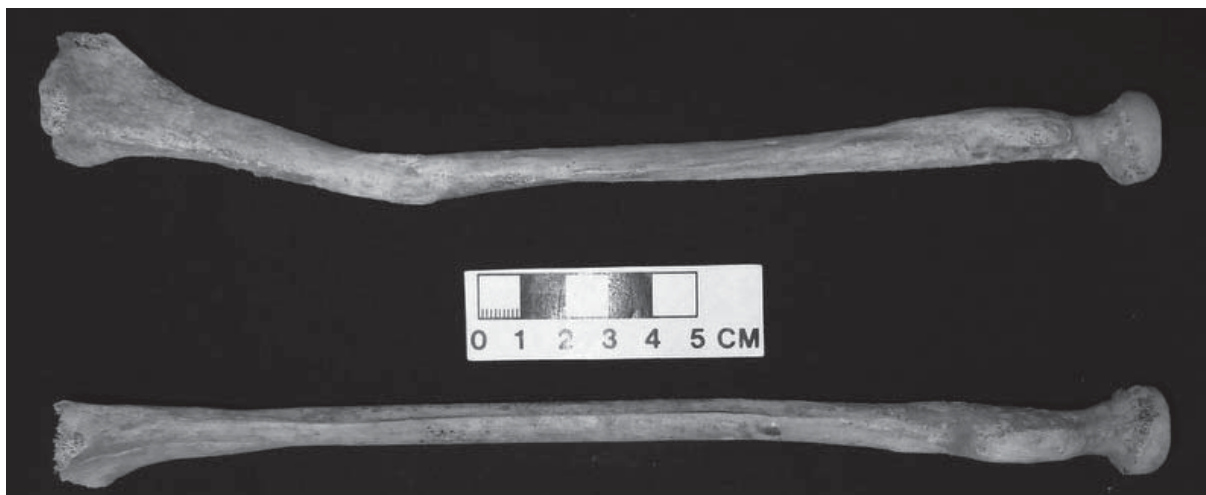

Fig. 7: Healed fracture of right radius with angulation; left radius for comparison. F008 SK01 (photo: Tina Jakob)

21 Roberts and Manchester 1995: 131.

22 So-called transitional vertebrae, Barnes 1994: 79–80.

23 Roberts and Manchester 1995: 57.

24 Case et al. 2006: 5–9.

25 Judd 2012: 71.



fusion of the first two thoracic vertebrae and the right sacro-iliac joint, with the left joint also showing signs of joint degeneration, but no fusion.

LATER BURIALS (NEW KINGDOM–NAPATAN OR EARLY MEROITIC)

A number of burials cannot be dated accurately and these are discussed in the following paragraphs. Feature F028A contained the remains of four adult individuals – one female and three males. The bones of F028A SK01, the female individual, were heavily disturbed and no age estimate was possible, while F028A SK03 was a young adult male (17–25 years) and the remaining two individuals were both young-middle adults (26–35 years). Stature estimates showed that this group included the shortest and the tallest individuals of MOG034. F028A SK01 was short, reaching only 146.98cm, while F028A SK04 was the tallest with 182.5cm. None of the individuals showed evidence for congenital conditions, non-specific infectious disease, joint disease or trauma. Dental disease occurred in F028A SK01 – four mandibular teeth were lost ante-mortem and four periapical lesions had formed in the maxilla. This individual also had cribra orbitalia. F028A SK04 had four teeth with linear enamel hypoplasia, but this and the female were the only individuals with preserved teeth, making it difficult to assess levels of non-specific stress.

Skeleton F028A SK02 had a large osteoma (30x25mm) on the right parietal bone. This new bone growth is classified as a benign tumour²⁶ and would not have caused any health problems, but a distinctive bulge would have been visible on the individual's head.

The following three individuals (F031 SK01, F031A SK01 and F108 SK01) can be dated to the late New Kingdom or the Napatan period.²⁷ F108 SK01 is a non-adult aged 9.5–14.5 years based on the development of the dentition. This individual had a retained deciduous canine, with the permanent canine remaining unerupted. F031 SK01, a male aged 36–45 years and a stature of 168.61cm, was the only individual with dental caries; a small caries lesion has affected one of the six preserved teeth (fig. 8). F031A SK01, a young-middle adult female had no teeth preserved, but her spine and shoulder showed signs of joint disease. Joint disease was also present in the spine of F031 SK01, leading to fusion of the last



Fig. 8: Caries on left maxillary second premolar of F031 SK01 (photo: Tina Jakob)

lumbar vertebra and first sacral segment, in addition some extra-spinal joints showed degenerative changes. This individual also had lamellar new bone formation on the right fibula, indicating a non-specific infection, and a healed fracture of the left fibula, with some evidence for post-traumatic infection.

Another three individuals (F033A SK01 and SK02, and F109 SK01) are tentatively dated to the Napatan period.²⁸ F109 SK01, a 9.5–14.5 year old non-adult, had evidence for non-specific stress in form of linear enamel hypoplasia and cribra orbitalia. Eleven teeth showed one or more lines, hinting at recurrent health and nutritional problems when these teeth were forming. Dental calculus was the only other dental disease present. However, this individual also had premature fusion of the sagittal suture (fig. 9) – a congenital defect.²⁹ Premature fusion of any of the major cranial sutures usually leads to deformation of the cranium, but in this individual no visible distortion was present. This indicates that the suture only fused after the cranium had already reached its adult size. F033A SK01, a well preserved 8–10 year old, was placed directly on top of F033A SK02, an old adult male.³⁰ The non-adult had dental calculus and seven teeth with linear enamel hypoplasia. Thoracic vertebrae T11 and T12 had assumed lumbar morphology (transitional vertebrae), in addition to having only four lumbar vertebrae, indicating a congenital condition. The old male F033A SK02 was 165.71cm tall and had a very wide range of pathological conditions, includ-

²⁶ Capasso 1997: 615.

²⁷ Weschenfelder, this volume.

²⁸ Weschenfelder, this volume.

²⁹ Barnes 1994: 154.

³⁰ Weschenfelder, this volume.

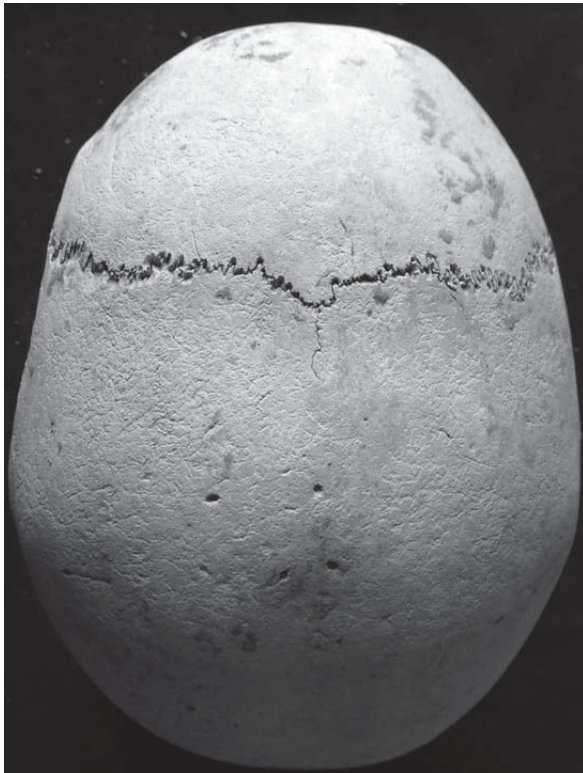


Fig. 9: Premature closure of sagittal suture of F109 SK01 (photo: Tina Jakob)




Fig. 10: Blunt-force trauma on posterior left parietal bone of F033A SK02 (photo: Tina Jakob)

ing dental calculus, periodontal disease and five periapical lesions. Interestingly, this individual also had transitional vertebrae, affecting T11 and T12, as seen in F033A SK01. The fifth lumbar vertebra had a separated neural arch (spondylolysis). Joint disease occurred on most vertebrae, having led to the fusion of two cervical vertebrae, and extra-spinal joint disease occurred in almost all joints. However, the most striking observations related to a number of healed fractures – the left parietal bone showed a small depression fracture (fig. 10), caused by blunt-force trauma, the right clavicle was fractured and the right hand had two fractured bones. This individual also had a healed fracture of the coccyx. It is unlikely that the blunt-force trauma was caused by an accident, while all other injuries could have been sustained during everyday activities. Small circular or oval depression fractures are usually caused by a blow to the head with a blunt object such as a club or stone.

Of later Napatan or Early Meroitic date³¹ are a number of individuals that will be briefly discussed here.³² F030 SK01 is the youngest individual found at MOG034; based on long bone length this is a

preterm fetus aged 36–39 weeks in utero. F033 SK01 and SK02 are both also non-adults, although slightly older at 3–9 months and 1–2 years of age. Only F033 SK01 had evidence for disease. Extensive porous new bone had formed on a number of skeletal elements, including the maxilla, mandibular rami and some cranial bones, scapulae, ribs and long bones of the extremities. The nature of the newly formed bone and pattern of bones affected can be found in individuals suffering from scurvy (vitamin C deficiency), although a non-specific infectious disease is more likely, assuming that fresh produce was available on a regular basis. The porous nature of the newly formed bone indicates that the disease was still active at the time of death. F034B SK01, an older female, suffered a periapical lesion, but showed no other evidence for dental disease. However, her right scapula had a separated tip of the acromion process (fig. 11); this is the second case of *os acromiale* in skeletons from MOG034.³³

31 Weschenfelder, this volume.

32 However, F033 SK03 and F034 SK01, both dated to the Late Napatan/Early Meroitic period, have not been analysed yet.

33 The other individual was F025 SK01.



Fig. 11: Right scapula, acromion process with os acromiale of F034B SK01 (photo: Tina Jakob)

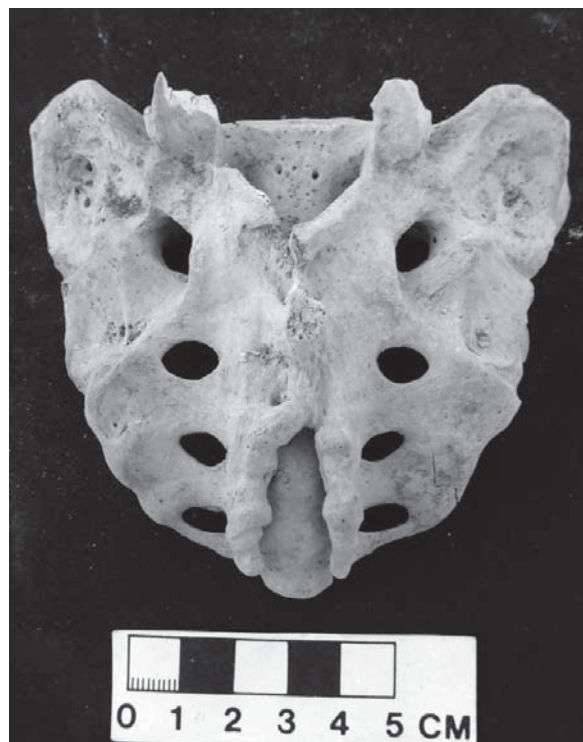

Fig. 12: Neural arch defect on posterior aspect of sacrum of F025 SK03 (photo: Tina Jakob)

EARLY MEROITIC BURIALS

F025 SK02, a 2–4 year old, is of probably Early Meroitic date.³⁴ Again, no pathological lesions were observed, but both mandibular deciduous canines had defective enamel. Birth trauma, but also malnutrition have been named as factors leading to defects in enamel formation.³⁵ F025 SK03, a young adult female, was radiocarbon-dated to the Early Meroitic period. She was rather small with 147.34cm and had cribra orbitalia and five teeth with enamel hypoplasia. Several teeth showed dental calculus. She also had six lumbar vertebrae, instead of five, and the last two segments of the sacrum showed a neural arch defect (fig. 12).

CONCLUSION

While it is difficult to come to definitive conclusions based on a relatively small number of individuals dating to such a temporally disparate group, certain trends and observations are possible that attest to the importance of these unique burial groups. Due to the combination of excellent excavation tech-

niques and favorable preservation it was possible to record a wide range of biological data. The Terminal Neolithic cemetery of F072 stands out with its large proportion of non-adult individuals and presence of non-specific stress indicators. Frequencies of dental disease in form of periapical lesions were generally high in most time periods and with the virtual absence of dental caries this is an unusual finding. A range of congenital conditions was observed in individuals dating to all time periods and this is likely indicative of isolated population groups. It is interesting that a comparatively large number of individuals had spondylolysis (three individuals) or os acromiale (two individuals), but with the etiological factors still ill understood, this is difficult to evaluate. The relatively high number of healed fractures is also noteworthy. Few adult individuals lived to reach old age and many of them showed degenerative joint changes. It will be interesting to see whether these preliminary observations will be supported by future excavations of MOG034.

³⁴ Weschenfelder, this volume

³⁵ Mukhopadhyay et al. 2014: 44.



BIBLIOGRAPHY

- Barnes, E. (1994): *Developmental Defects of the Axial Skeleton in Paleopathology*. Niwot, CO.
- Buikstra J. E. and D. H. Ubelaker (1994): *Standards for Data Collection from Human Skeletal Remains*. Archeological Survey Research Seminar S. 44. Fayetteville, AR.
- Byers, S. (2010): *Introduction to Forensic Anthropology*. London.
- Capasso, L. (1997): Osteoma: palaeopathology and phylogeny, *International Journal of Osteoarchaeology* 7(6): 615–620.
- Case, D. T., S. E. Burnett and T. Nielsen (2006): Os acromiale: Population differences and their etiological significance, *HOMO* 57(1): 1–18.
- Judd, M. (2001): The human remains. In: Welsby, D. A. (ed.): *Life on the Desert Edge: Seven Thousand Years of Settlement in the Northern Dongola Reach, Sudan*. Sudan Archaeological Research Society Publication 7. London: 458–543.
- Judd, M. (2008): The skeletal catalogue. In: Salvatori, S. and D. Usai (eds.): *A Neolithic Cemetery in the Northern Dongola Reach: Excavations at Site R12*. London: 83–104.
- Judd, M. (2012): Gabati. A Meroitic, post-Meroitic and Medieval Cemetery in Central Sudan. Volume 2: *The Physical Anthropology*. British Archaeological Reports International Series 2442. Oxford.
- Larsen, C. S. (2015): *Bioarchaeology: Interpreting Behavior from the Human Skeleton*. 2nd ed. Cambridge.
- Lewis, M. E. and R. Gowland (2007): Brief and precarious lives: Infant mortality in contrasting sites from medieval and post-medieval England (AD 850–1859), *American Journal of Physical Anthropology* 134(1): 117–129.
- Mukhopadhyay S., P. Roy, B. Mandal, C. Ghosh and B. Chakraborty (2014): Enamel hypoplasia of primary canine: Its prevalence and degree of expression, *Journal of Natural Science, Biology, and Medicine* 5(1): 43–46.
- Roberts, C. A. and K. Manchester (1995): *The Archaeology of Disease*. Stroud.
- Simalcsik, A., G. Miu, V. M. Groza and R. D. Simalcsik (2011): Regarding occult spinal dysraphism (spina bifida occulta), focusing especially on a medieval population from Iași, *Analele Științificele Universității "AL. I. Cuza" Iași, s. Biologie animală* 57: 131–140.
- Solomon, L., D. Warwick and S. Nayagam (2015): *Apley and Solomon's Concise System of Orthopedics and Trauma*. Boca Raton.
- Weschenfelder, J. and G. Rees (2014): Preliminary report of the first field season of the Kerma cemetery MOG034 on Mogratt Island, Sudan, *Der antike Sudan. MittSAG* 25: 145–154.

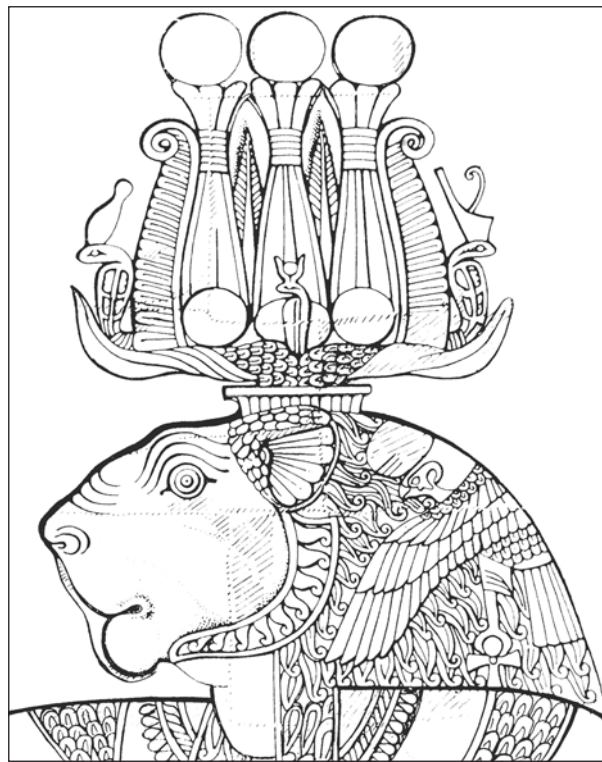
ZUSAMMENFASSUNG

Dieser vorläufige Bericht befasst sich mit der bioarchäologischen Analyse der menschlichen Skelettreste vom Fundplatz MOG034 der Mogratt Island Archaeological Mission (MIAMi) aus den Kampagnen 2014 und 2015. Bisher konnten 43 der ausgegrabenen 52 Skelette analysiert werden. Die Analyse beinhaltet die Erfassung der Skeletterhaltung, die Alters- und Geschlechtsdiagnose sowie die Körperhöhenbestimmung. Desweiteren erfolgte eine makroskopische paläopathologische Beurteilung.

Auffällig war, dass der spätneolithische Friedhof F072 eine Vielzahl an nichterwachsenen Individuen enthielt. Keiner der Erwachsenen erreichte ein hohes Lebensalter. Erkrankungen, die auf Mangelernährung und Gesundheitsprobleme im Kindesalter hindeuten, waren häufig zu beobachten. Dagegen waren Zahnerkrankungen und Infektionskrankheiten selten. Fälle von kongenitalen Anomalien deuten auf eine isolierte Menschengruppe hin. Eine kleine Gruppe von Individuen der Kermazeit belegte eine Vielzahl von Erkrankungen, einschließlich Zahnabszessen, kongenitalen Anomalien und Infektionen der Atemwege. Degenerative Gelenkerkrankungen der Wirbelsäule und anderer Gelenke kamen häufig vor und müssen im Zusammenhang mit dem höheren Lebensalter dieser Individuen gesehen werden. Die zeitlich späteren Bestattungen des späten Neuen Reiches, der napatanschen Zeit und der frühmeroitischen Epoche zeigten eine Reihe pathologischer Veränderungen, darunter auch den einzigen Fall von Zahnkaries. Ein männliches Individuum besaß mehrere verheilte Knochenbrüche, darunter auch eine Fraktur des Schädeldaches, die durch stumpfe Gewalteinwirkung entstanden ist.

Die relativ kleine Gruppe von Skeletten erlaubte eine Vielzahl von interessanten Beobachtungen. Weitere Ausgrabungen werden es ermöglichen, diese vorläufigen Ergebnisse zu unterstützen und Vergleiche mit anderen chronologisch und geographisch nahestehenden Skelettgruppen anzustellen.

MITTEILUNGEN DER
SUDANARCHÄOLOGISCHEN
GESELLSCHAFT ZU BERLIN E.V.



HEFT 26
2015



HERAUSGEBER:	Sudanarchäologische Gesellschaft zu Berlin e.V. c/o Humboldt-Universität zu Berlin Institut für Archäologie – Lehrbereich Ägyptologie und Archäologie Nordostafrikas Unter den Linden 6 • 10099 Berlin
VERANTWORTLICH FÜR DIE HERAUSGABE:	Angelika Lohwasser
LAYOUT & SATZ:	Frank Joachim
ERSCHEINUNGSORT:	Berlin
INTERNETPRÄSENZ:	www.sag-online.de
BANKVERBINDUNG DER SAG:	Deutsche Bank 24 AG BLZ 100-700-24 BIC DEUTDE3333 Kto.-Nr. 055-55-08 IBAN DE36100700240055550800

Die Zeitschrift DER ANTIKE SUDAN (MittSAG) erscheint einmal im Jahr und wird an die Mitglieder der Sudanarchäologischen Gesellschaft kostenlos abgegeben. Preis pro Heft: 19,50 Euro + Versandkosten. Die in den Beiträgen geäußerten Ansichten geben nicht unbedingt die Meinung des Herausgebers wieder. Die „Richtlinien für Autoren“ finden Sie unter www.sag-online.de, wir senden sie auf Anfrage auch gerne zu.

© 2015 Sudanarchäologische Gesellschaft zu Berlin e.V.
Nachdruck, auch auszugsweise, nur mit Genehmigung der Gesellschaft.

SUDANARCHÄOLOGISCHE GESELLSCHAFT ZU BERLIN E.V.

Angesichts der Tatsache, daß die globalen wirtschaftlichen, ökonomischen und politischen Probleme auch zu einer Gefährdung der kulturellen Hinterlassenschaften in aller Welt führen, ist es dringend geboten, gemeinsame Anstrengungen zu unternehmen, das der gesamten Menschheit gehörende Kulturerbe für künftige Generationen zu bewahren. Eine wesentliche Rolle bei dieser Aufgabe kommt der Archäologie zu. Ihre vornehmste Verpflichtung muß sie in der heutigen Zeit darin sehen, bedrohte Kulturdenkmäler zu pflegen und für ihre Erhaltung zu wirken.

Die Sudanarchäologische Gesellschaft zu Berlin e.V. setzt sich besonders für den Erhalt des Ensembles von Sakralbauten aus meroitischer Zeit in Musawwarat es Sufra/Sudan ein, indem sie konservatorische Arbeiten unterstützt, archäologische Ausgrabungen fördert sowie Dokumentation und Publikation der Altertümer von Musawwarat ermöglicht. Wenn die Arbeit der Sudanarchäologischen Gesellschaft zu Berlin Ihr Interesse geweckt hat und Sie bei uns mitarbeiten möchten, werden Sie Mitglied! Wir sind aber auch für jede andere Unterstützung dankbar. Wir freuen uns über Ihr Interesse!

Mitgliedsbeiträge jährlich:
Vollmitglied: € 65.- | Ermäßiggt: € 35.- | Student: € 15.- | Fördermitglied: mind. € 250.-

ISSN 0945-9502

Der antike Sudan. Mitteilungen der Sudanarchäologischen Gesellschaft zu Berlin e.V.

Kurzcode: MittSAG

Heft 26 • 2015



EDITORIAL	5
ÜBERSICHTSKARTE	6
NACHRICHTEN AUS MUSAWWARAT	
Claudia Näser <i>Site management at Musawwarat es-Sufra 2014/15: concepts, measures and perspectives</i>	7
Peter Becker <i>Löwentempel Musawwarat es-Sufra – die Renovierung des Dachtragwerks 2014/15</i>	27
Claudia Näser & Manja Wetendorf <i>The Musawwarat pottery project 2014/15</i>	35
FRITZ-HINTZE-VORLESUNG	
Friederike Jesse <i>Bollwerk im Niemandsland: Die Festung Gala Abu Ahmed zur Zeit der Pharaonen</i>	75
AUS DER ARCHÄOLOGIE	
Yahia Fadol Tahir & Ahmed Hamid Nassr <i>Paleolithic stone tools of El-Ga'ab depression A techno-typological study from the surface collection</i>	95
Angelika Lohwasser, Jana Eger & Tim Karberg <i>Das Projekt Wadi Abu Dom Itinerary (W.A.D.I.) Kampagne 2015</i>	109
Annett Dittrich, Kerstin Geßner, Sayantani Neogi, Maciej Ehlert & Nadine Nolde <i>Holocene stratigraphies and sediments on Mogratt Island (Sudan) – The second season of the Late Prehistoric Survey 2014/15</i>	123
Jens Weschenfelder <i>The Terminal Neolithic cemetery in the funerary landscape of MOG034, Mogratt Island, Sudan</i>	145
Jens Weschenfelder <i>Preliminary report of the second and third field seasons at the Bronze Age cemetery MOG034 on Mogratt Island, Sudan</i>	153
Tina Jakob <i>Preliminary Bioarchaeological Analysis of the Human Remains from Mogratt Island (MOG034), 2014 and 2015</i>	169
Gareth Rees, Miriam Lahitte & Claudia Näser <i>The Fortresses of Mogratt Island Project</i>	177
Gemma Tully <i>Community Archaeology in Sudan: Discovering Mogratt Island together</i>	201



VARIA

- Uwe Sievertsen
Die Profanarchitektur der napatanschen Epoche 205
- Kumiko Saito
*The matrilineal royal Succession in the Empire of Kush: A new proposal Identifying
the Kinship Terminology in the 25th and Napatans Dynasties as that of Iroquois/Crow* 233
- Angelika Lohwasser
Khonsu sitting IN Jebel Barkal 245
- Uroš Matić
Die „römischen“ Feinde in der meroitischen Kunst 251
- Joanna Then-Obłuska
“Jewels of Ancient Nubia” – a glance through the eye bead from Berenike 263
- Alexey K. Vinogradov
The Many-Eyed Thinker from Meroe 267
- Michael H. Zach
Meroe in der österreichischen Reiseliteratur des 19. Jahrhunderts 277